

Activities Report of Operation Straight Spine

2015 Kolkata, India

Dr UJJWAL K DEBNATH

HOSPITAL:

RAMAKRISHNA MISSION SEVA PRATISTHAN



TEAM MEMBERS FOR OSS 2015:

INDIA:

Ujjwal K Debnath, FRCS – Orthopaedic Spine Surgeon

UK:

Neena Seth, MD – Consultant Anaesthesiologist
Caroline Davies, MD – Consultant Anaesthesiologist
Meera Alexander, MD - Consultant Anaesthesiologist
Priya Krishnan, MD – Consultant Anaesthesiologist
Kate Masters, RN – Scrub Nurse
Marian Barry, RN – Scrub Nurse
Rachel Hunt, RN – Paediatric Nurse Specialists

ITALY:

Dr Francesco Cacciola, MD – Consultant Neurosurgeon

US:

Johanna Ziegler, CST – OR Scrub Tech
Heather Greenberg – Neuromonitoring Specialist
Mark Webster – Globus Medical Representative
Chad Freundlich - Globus Medical Representative

BANGLADESH:

Col (Dr) Salim-Ur-Rahman, MS (Orth),- Spinal Fellow

SPONSORS:

We would like to acknowledge the following sponsors who generously donated to support Operation Straight Spine:

Emirates Airlines Foundation
Globus Medical Inc.
Lehigh Valley Hospital and Health Network
Fronheiser Family Foundation
Laboni Choudry, MD
Spine Education and Research Foundation
St. Lukes Hospital and Health Network
Surgery Center of Allentown
SPIRIT India, Kolkata
Guys Hospital, London

Arrival of Team

13th Feb 2015

Dr Ujjwal K Debnath arrived in Kolkata from London by emirates airlines at 1915.

14th Feb 2015 (sat)

Two anaesthesiologist from UK, Dr Neena Seth and Dr Meera Alexander arrived in Kolkata at 0740AM. They flew from London (via Dubai, UAE) on Emirates Airlines. The team is met by Dr. Debnath at the airport and they travel to the Tollygunge Club for the stay during the period.

Both Dr Neena and Dr Meera went to the hospital and reviewed all the patients by the afternoon and decided the dates of surgery for each patient.

The list consisted of 10 children with scoliosis/kyphosis and 3 adults with TB spine patients. The scoliosis patients were 3 AIS, 4 Congenital, and 2 EOS (requiring revision of growing rod 4.5 system). Dr Debnath was confirmed by Ramakrishna Mission Hospital regarding the receipt of all the implants and instruments sent by Globus Medical Inc from US via Chennai. Dr Debnath had organized the spinal instruments and implants to for the 1st case to undergo autoclave for the 1st case on 16th Feb 2015.

15th FEB 2015 (sun)

The 3 members from UK, 2 members from US and 1 from Italy arrived at Kolkata by Emirates airlines at 740AM. Dr Debnath had arranged them to be met by receiving team i.e. Dr Salim Ur Rahman (Spinal Fellow from Bangladesh) at the airport and were transported to Tollygunj Club. In the afternoon, the team members met formally at the hospital for planning out the week ahead. All patients were assessed by Ms Rachel Hunt (Specialist Scoliosis Nurse) and were given preoperative directions. Patients were prioritized according to the logistics involved each day of the week and listed for surgery.

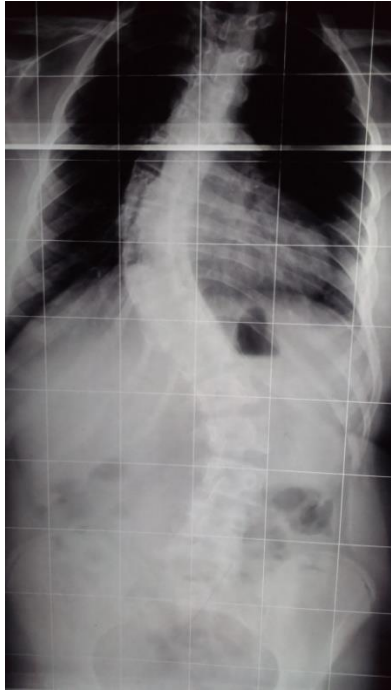
In the evening, everyone had an early night.

16th Feb 2015 (Mon)

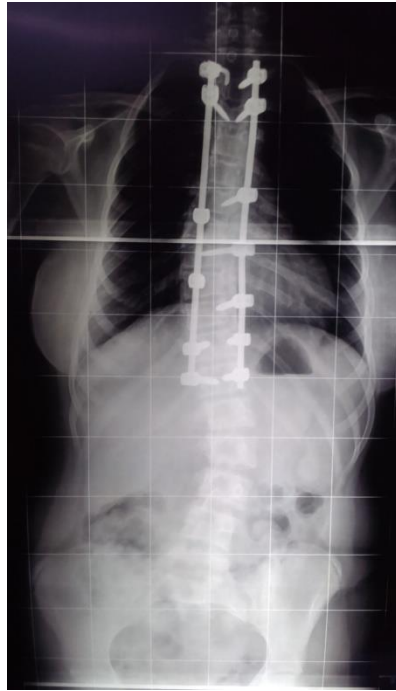
First day at Surgery:

The two expert anaesthesiologist prepared the anaesthetic room by 10-11AM. They anaesthetized our first case and Neural monitor wiring was completed by 12noon.

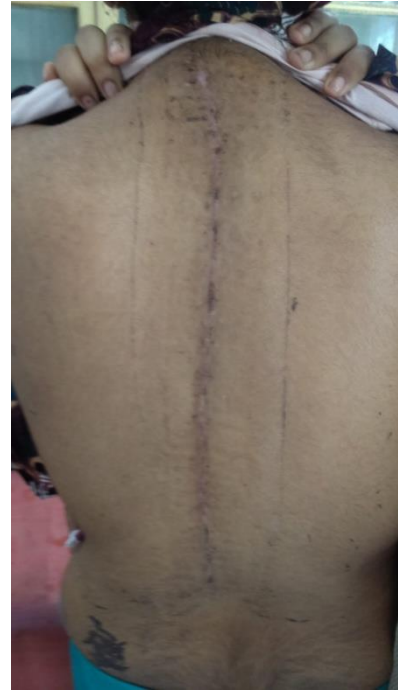1. Tiasha Ghosh (12 year old girl) with right sided thoracolumbar Adolescent Idiopathic scoliosis. Primary curvature measuring 63° from T3 to T11 and the secondary curvature T12 to L3 measuring 50°. She underwent Pedicular Screw Fixation from T3-T12 with sub laminar hook at T2. Rods were inserted and derotation & segmental correction was done with bone graft. After surgery patient was transferred to ICU by 630PM.



Pre op- AP X-rays



2weeks Post -op AP X-rays



Tiyasha in clinic



Beaming Tiyasha with happiness for reduced rib hump

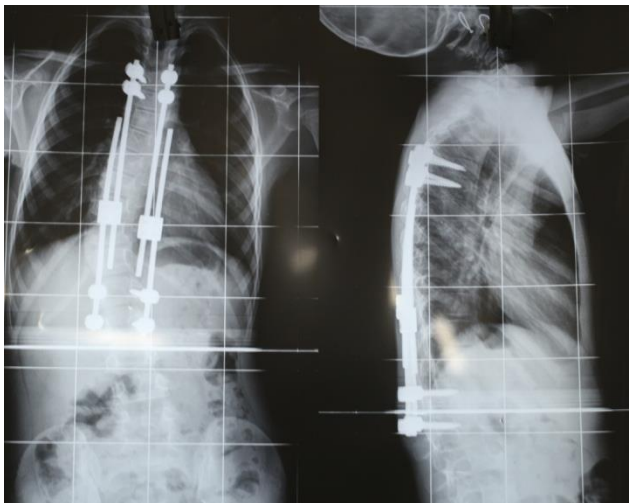The team was joined by Mike Webster and Chad Freundlich (both Globus Medcal Reps from USA) by afternoon. Their joining the team in the OR was of great help in getting the implants ready on OR table.

Following the post op stabilization the team was escorted back to Tollygunj club by 9PM. Everyone had dinner at the club and had early night.

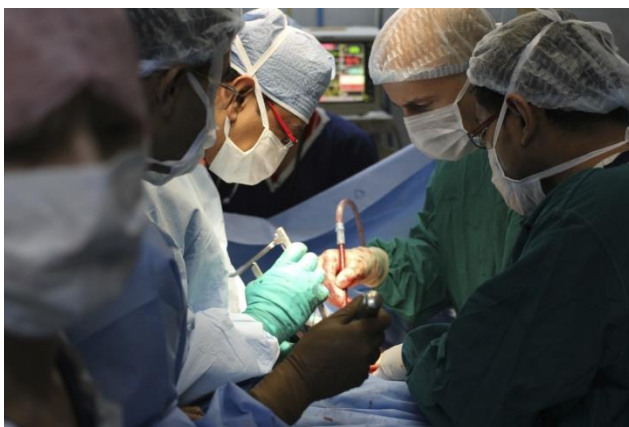17th Feb 2015 (Tues)

The team started by hospital bus from Tollygunj club by 830AM after a full breakfast. Dr Debnath joined us at the hospital and the team prepared the first case which was a revision followed by patient with removal of implants and possibly further surgery.

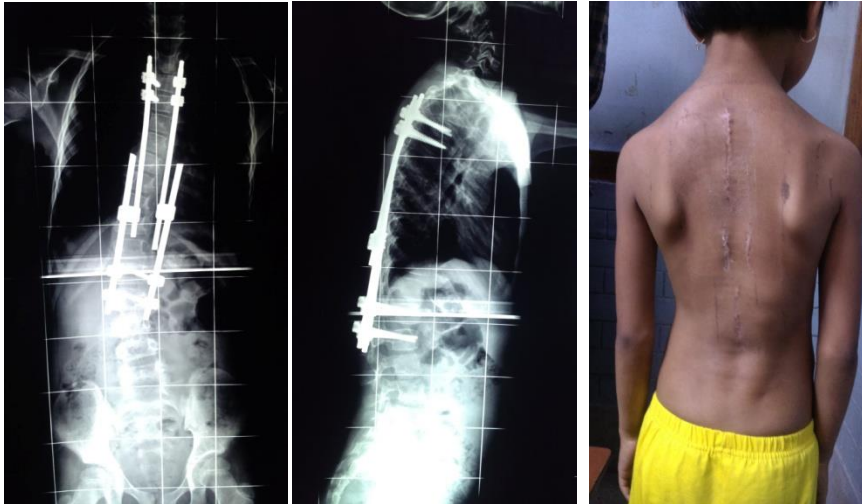
2. Tithi Pan, 7year/Female, This girl was implanted with bilateral growing rods (locally made 3.75mm rod system) when she was 5year old for her early onset curvature. She has grown taller now and radiological images of spine showed the screws were loose proximally (T2) and distally (L2). She underwent re-surgery with removal of previous implants. The proximal screws were reinserted in a different direction and longer screws were used for a better fixation into the body of T2 & T3 (4.5mmx30mm pedicle screws). The distal screws were reinserted similarly in L1 & L2 (5mmx40mm pedicle screws). 4.5mm rods in the upper segment & 5.5mm in the lower segment were used and curvature was corrected.



Pre op AP and Lat X-rays



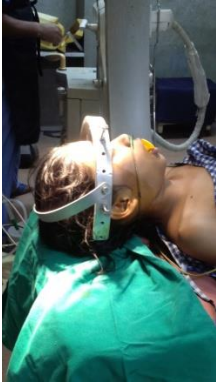At surgery Dr Debnath & Dr Cacciola



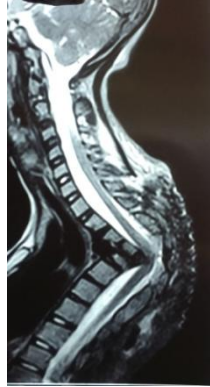
Post op AP & Lat X-rays

Tithi has grown tall

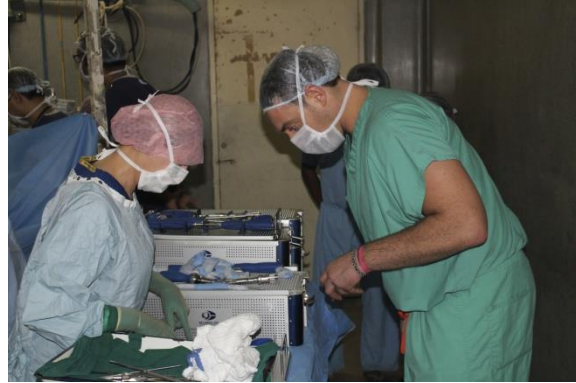3. Himanshi Choudhury, 10 year/Female, This girl had undergone a previous surgery for TB spine with collapse of T4/5 in 2008 with posterior alone debridement and fusion. She was seen by Dr Debnath in the clinic with severe cervico-thoracic progressive loss of sagittal balance. She was neurologically intact. X-rays had suggested proximal screw pull out from T2. It was decided to remove the implants followed by MRI scan to see the status of the spinal cord. She underwent posterior removal of all implants and applied bone grafts locally. She was left in cervical collar post operatively. During the electrophysiological studies at surgery it was observed that her potentials for motor in both lower limbs were very low. She was doing well post-operatively. She underwent MRI scan after she recovered. She was discharged a week later when her wounds showed signs of healing. After 13 days of surgery she returned from home with complete paralysis of her both the lower limbs (MRC gr 2 to 3). She was put on Halo Pelvic traction (graduated to 5Kg in the head end and 10Kg at the foot end) with a metal Halo around the Head. She tolerated the Halo well for the last two weeks.
 She awaits for her surgery i.e. Revision surgery with in situ fusion and pedicle instrumentation from C7/T1 to T7/8 by 1st week of April 2015.
 The team finished the evening at 9PM. Drs Neena and Meera stayed on to care for the patients in ICU. They returned late at 11PM and had late dinner. Tonight's dinner was take away menu from Tero Parbon (authentic Bengali cuisine).



Himanshi being treated with Halo



MRI scan showing C-T kyphosis & spinal cord compression

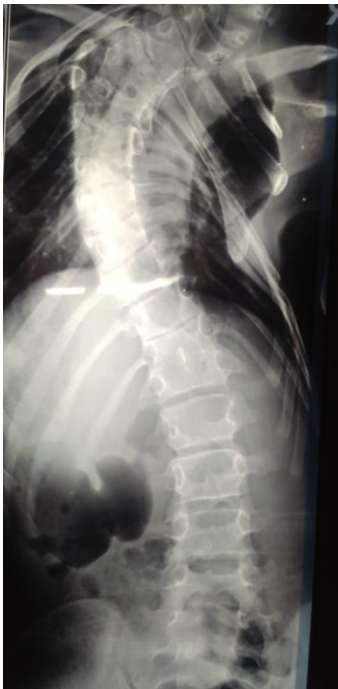

Chad showing implants to sister Marian

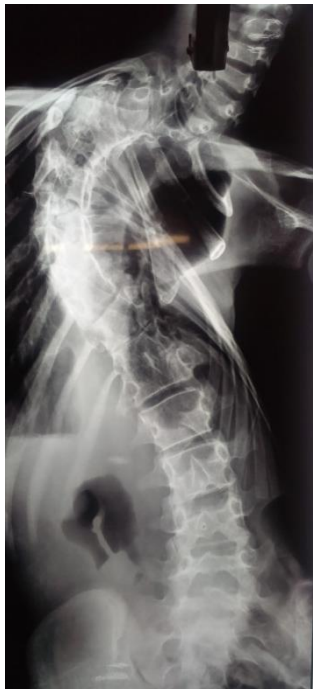18th Feb 2015 (Wed)

The team 'OSS' left the Tolly club by the bus at 830AM. After discussion regarding the two cases that were planned for the day the first patient was sent for at 9AM.

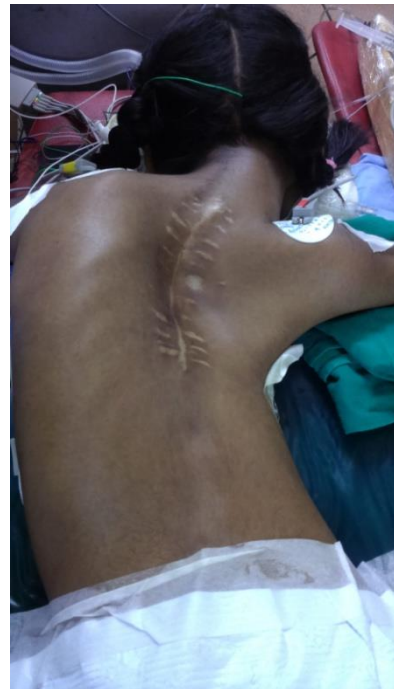- Ritama Acharjee, 11year/Female, was first treated 3 years ago for a congenital dorsal spinal deformity elsewhere with convex epiphyseodesis. The girl was diagnosed to have a unilateral unsegmented bar with multiple HemiV on the convex side. This girl continued to progress with her curvature (105°) and lost her standing balance.



Standing X-rays in Jul 2014

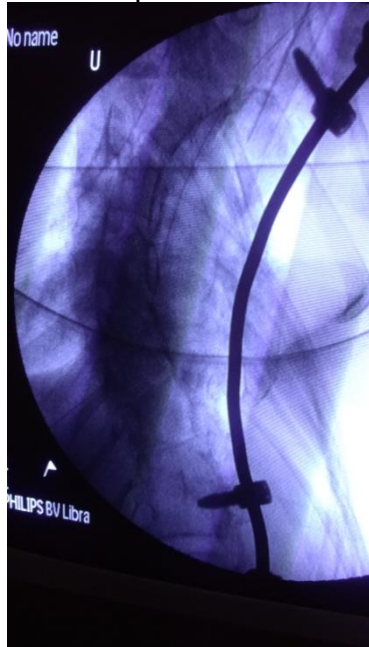


Standing X-rays in Feb 2015

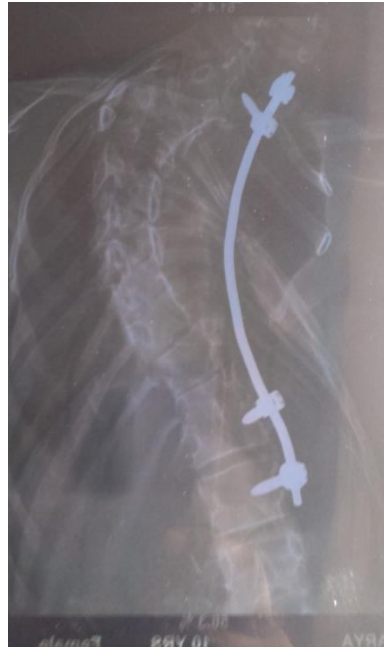

Patient positioned prone in OR

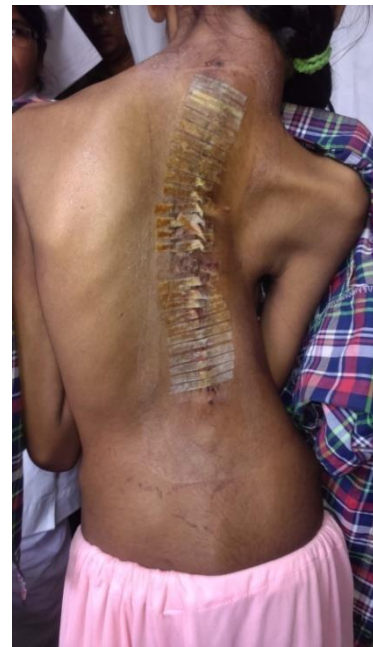She had increasing pelvic imbalance and progressive deterioration of her lung Function (less than 50% of normal) . Both anaesthesiologist were not sure of the post-operative respiratory recovery in the ventilation. The family of the patient was explained that she would not get much correction but the in-situ fusion will prevent her to deteriorate further in her lung function. She may be able to stand and walk better. On the balance of risk she underwent surgery. She had screw fixation on the right (concave side) proximally at C7 & T1 pedicle and distally at T12 & L1 pedicles. A 5.5 rod was prebent and fixed at both ends. The scapula was proximally very near the spine. The rod was allowed to be between the scapula and the spine.



Intra-operative film



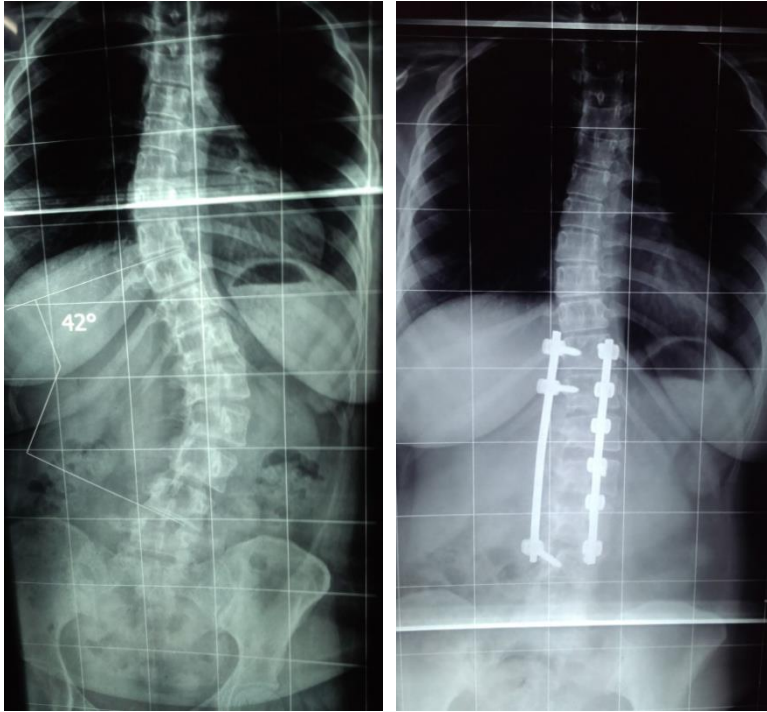
2 weeks post op X-rays



Ritama Standing well

She was in ICU for 2 days and was out of ventilation next day. She had uneventful recovery. The patient herself was pleased with her result. She was able to stand and walk better.

5. Nabanita Roy, 22 year/female, who was suppose to be married a year later was not happy with her AIS thoraco-lumbar curve measuring approximately 45°. It was decided that she will undergo fixation from T11 to L4. On the right side the pedicles were very thin in the Lumbar spine. Therefore, the L1, L2 and L3 vertebral screws couldn't be inserted. Therefore, pedicle screw fixation was possible at L4 alone. Derotation rod was applied on the convex side and Segmental correction was achieved. Post-operatively patient and family were pleased with the appearance.



Preoperative X-rays

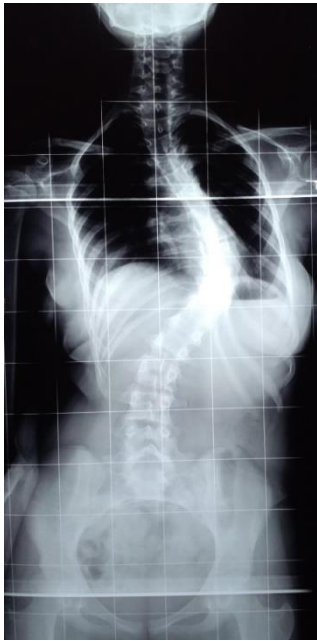Postoperative X-rays

Everyone finished the evening by 930PM. A late dinner at 1030PM from Tero Parbon (authentic Bengali Cuisine) at Tolly club followed by slumber and preparing for next day.

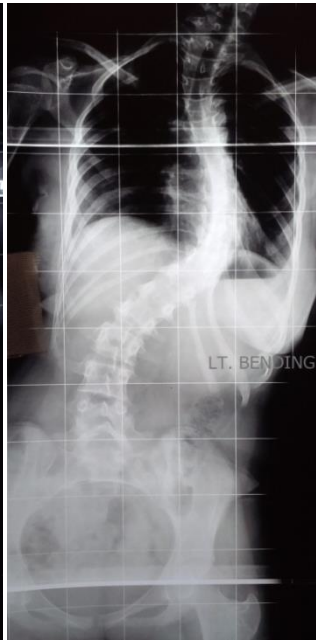
19th Feb 2015 (Thur)

The team prepared today for a surgery on a young girl with a stiff curve of 80°. A 5.5mm set was autoclaved today morning by requesting the authorities so that we could start the surgery by 11AM latest. The hospital issued a notice that next day Friday being holiday (in lieu of birth anniversary celebrations of Sri Ramakrishna Paramahansa) the OR will remain shut. Dr Debnath had to call upon a meeting with the head of the hospital (Swami Satyadevananda) and Matron requested them to help the 'OSS' team for at least one surgery since team anaesthetist can do only one case on Saturday. The head obliged and re organized the OR staff for Friday (20th Feb).

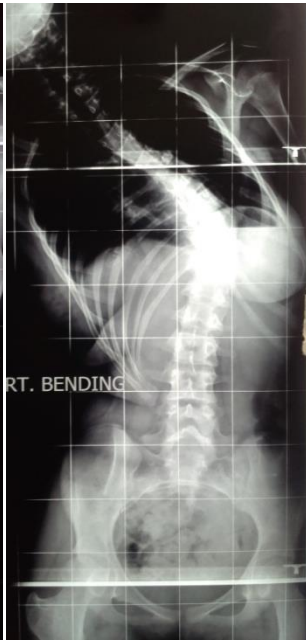
6. Debjani Halder, 13year/Female, right thoraco-lumbar AIS with flexibility less than 40% on bending films. The family had been very poor and was unable get the girl operated. Thus the delay in treatment leading to progression of the curve to a stiff one. She underwent a T3 to L1 fixation. She had left sided TP Hook at T3 & Sublaminar hook at T4 with Pedicle screws T7, T9, T11, T12, L1. She had the curve correction to 80%. She was transferred to ICU for the night. The team finished early by 9PM. They went to Dr Debnath's home to be with his 2month old baby girl. They had dinner at Dr Debnath's mother's home. They left for the hotel after midnight.



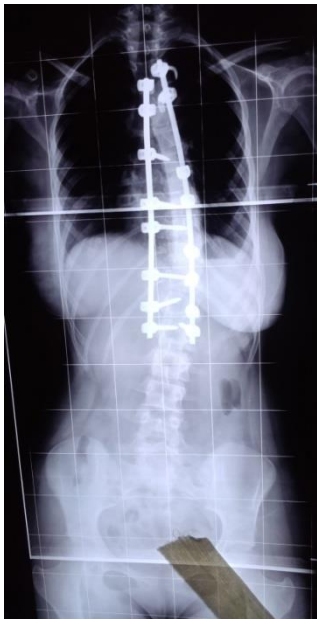Standing AP X-rays



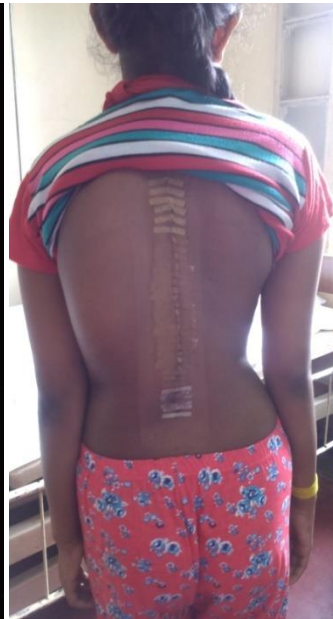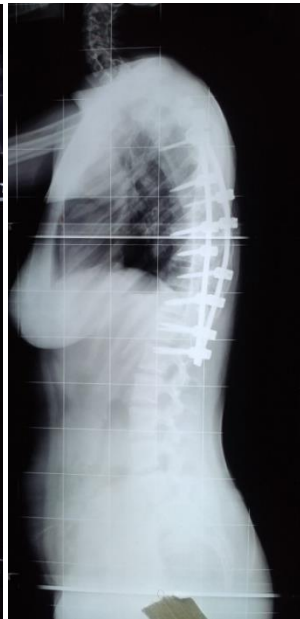
Left Bending X-rays



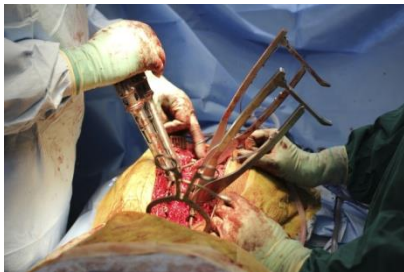Right Bending X-rays



Post op X-rays AP & Lateral



2 weeks Post op correction

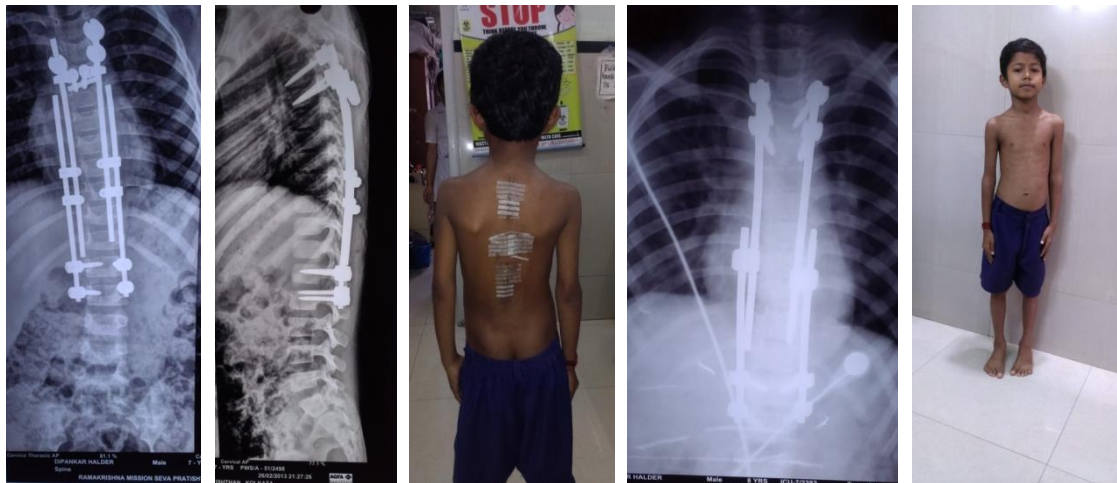

Segmental correction

20th Feb 2015 (Fri)

The team had a late start today since the hospital OR staff would be delayed as informed. The team started at 10AM and only patient who required surgery today was a revision of growing rod in a young boy who had previously 2 surgeries.

7. Dipankar Halder, 9 year/boy who had previous surgery in 2013 with a 3.75 locally made growing rod set from T4 to L2. He had loosening of the screws both proximally and distally. He underwent revision of his growing rods to a 4.5mm system.



X-rays showing loose screws

5days post op photographs & X-rays

Johanna Zeigler, US team member was supposed to leave on 21st Feb 2015 but she decided to continue since the team was short on expert scrub in theatre. Dr Debnath managed to rebook her ticket for 27th Feb 2015.

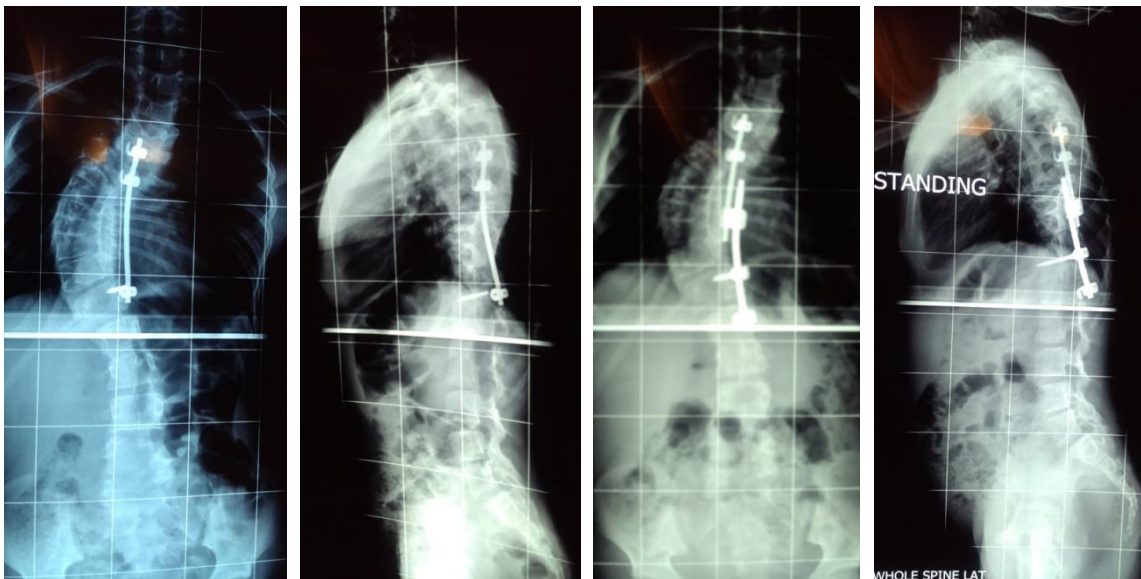
The team had a quiet dinner at the club and retired early.

21st Feb 2015 (Sat)

The team had an early start today.

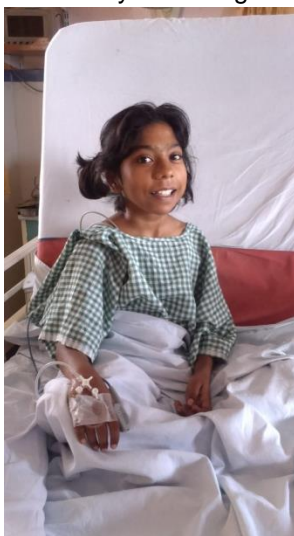8. Rukhe Jeba, 11year/female, was treated one year ago for a congenital dorsal scoliosis (unsegmented bar with hemivertebraes). She had undergone anterior release and posterior fusion with a single rod (Sublaminar hooks & pedicle screws and rods @ T4-T12). She had grown by an inch in the last one year. She came for follow up and was found to have a broken distal screw at T12. She needed revision fusion. She underwent posterior alone removal of screws and rod and revised with a growing rod 4.5mm system.

She had implantation of Sublaminar hook at T4,T5, L1 4.5mm x 30mm pedicle screw at T12 on left with CC rod and dominos (growing rod).



X-rays showing broken distal screw

X-rays showing revised instrumentation



Rukhe Jeba 2 days after surgery



Dr Neena, Marian, Rachel & Johanna with the children

The team finished early by 430PM and all wanted to have a dinner at Oberoi Grand Hotel. They left for Tolly Club and went for the dinner. The 4 members of the team (Dr Neena, Dr Meera, Marian and Rachel) were leaving for London in the morning on Sunday 22nd Feb 2015.

Transport was arranged for two anaesthesiologist (Dr Caroline Davies & Dr Priya Krishnan) who flew from London to Kolkata by Emirates to replace Dr Neena and

Dr Meera. They arrived by 1930hrs and duly escorted to Tolly club where they had a quiet dinner and had an early night.

22nd Feb 2015 (Sun)

Early morning at 530AM, team members (4) as mentioned above left for the airport. Dr Debnath went for a ward round at around 1030AM. Dr Debnath met the two anaesthesiologist in the afternoon at Tolly club. He discussed all the cases for the week ahead. Dr Caroline Davies wished to take rounds in the morning on Monday. Other members of the team had a rest day going around Kolkata.

23rd Feb 2015 (Mon)

The team started early today since the two anesthesiologist had to get acclimatized to the system in which they worked last year. One case was posted today.



Ward round with Dr Caroline Davies (Dipankar, Himanshi & Rukhe)

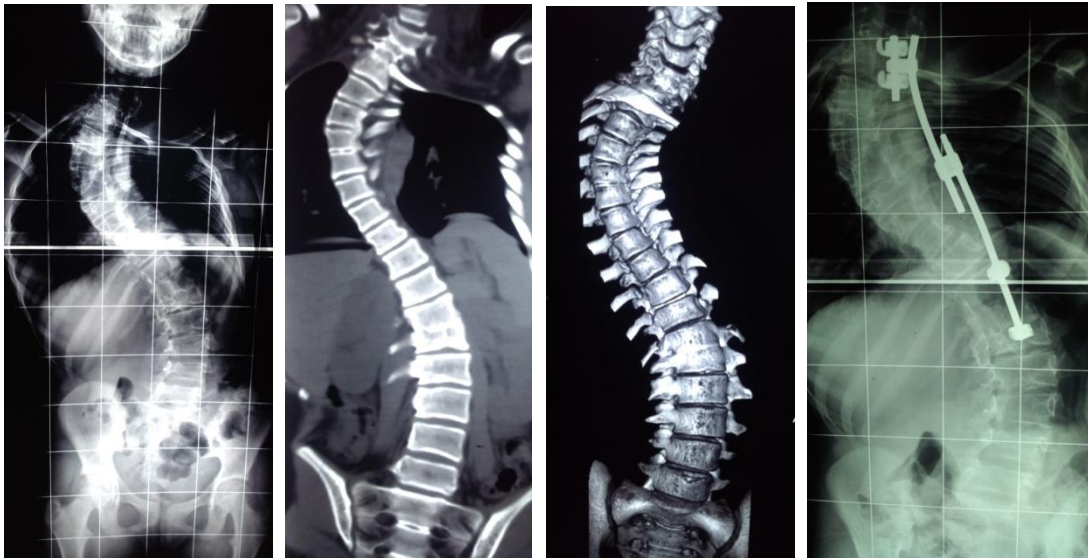
9. Sattar Ali Mallik, 26year/male, has a 8month history of TB spine with D5/6 collapse and abscess with upper motor neuron paralysis of his lower limbs. He has bladder and bowel dysfunction. He was in a long term catheter. He underwent posterior instrumentation from T2 to T8 and evacuation of abscess as well as decompression of the spinal cord at D5/6.

It was an early finish at 6PM today. Everyone went to Chinese restaurant 'The Wall' for a dinner.

24th Feb 2015 (Tues)

The team departed from Tolly Club at 830AM and everyone assembled at the hospital OR. The case for today was a 11 year old girl with congenital scoliosis which was progressive.

10. Priti Karar, 11 year/Female, Progressive congenital scoliosis with severe truncal imbalance. She has a long thoraco-lumbar curvature T2 to L1 measuring 70° with block Vertebrae at T2/3, T5/6 and T12/L1 levels. The curve itself behaving like it has an unsegmented bar in the concave side but 3D CT scan didn't reveal such a bar. There was no neurological deficit. But she had a large hairy pigmented patch on the lower back. It was decided that she will be fused when her growth is completed. She underwent a growing rod construct with proximal and distal hooks.



Following the surgery everyone prepared to be in Chinatown for a Chinese dinner at 'Golden Joy'. The dinner was over by 10PM and team was transported to Tolly Club.

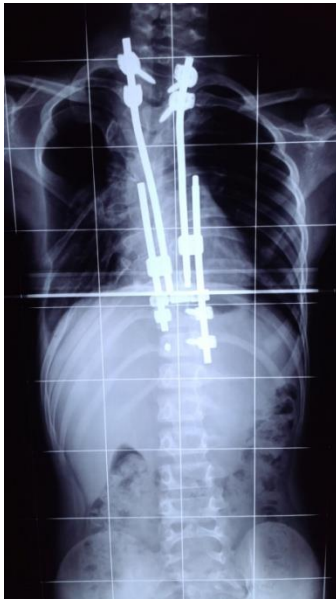
25th Feb 2015 (Wed)

Today the team had an early start since there were two cases booked for the day.

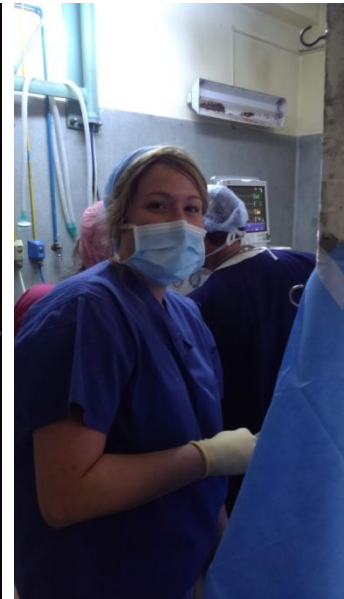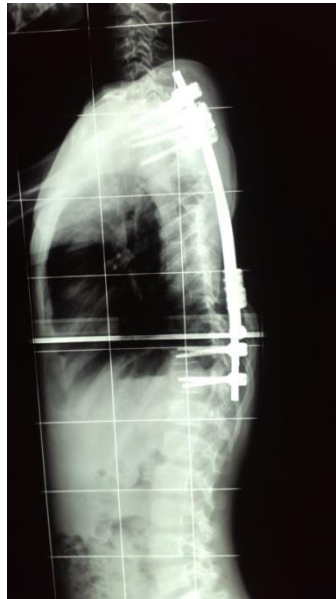11. Neal Lama, 9 year old male with congenital right thoracic scoliosis, absent ribs on the right hemithorax, L1-2 syrinx and a tethered spinal cord at L3. He was previously operated on in 2012 and had convex fusion at the apex of the curve and placement of "growing" rod construct on the left side with cervical lateral mass screws and 3.7mm rod at T10 and T11 and hook claw over the third rib on

the left. In Feb 2013, he underwent surgery which included sectioning of the filum terminale at L5-S1 and release of the tethered cord by a local neurosurgeon. The second part of the procedure included removal of the old instrumentation (which had lost purchase at the proximal rib claw) insertion of bilateral growing rod construct with T2 screw-hook claw and T10-11 screw distal foundation. In Feb 2014, he was scheduled for revision of the growing rod construct. The surgery was postponed due to unavailability of the 4.5mm system.

This year we revised the growing rod construct to 4.5mm system. The boy developed a pneumothorax and was treated with a chest drainage for 6days post-operatively.



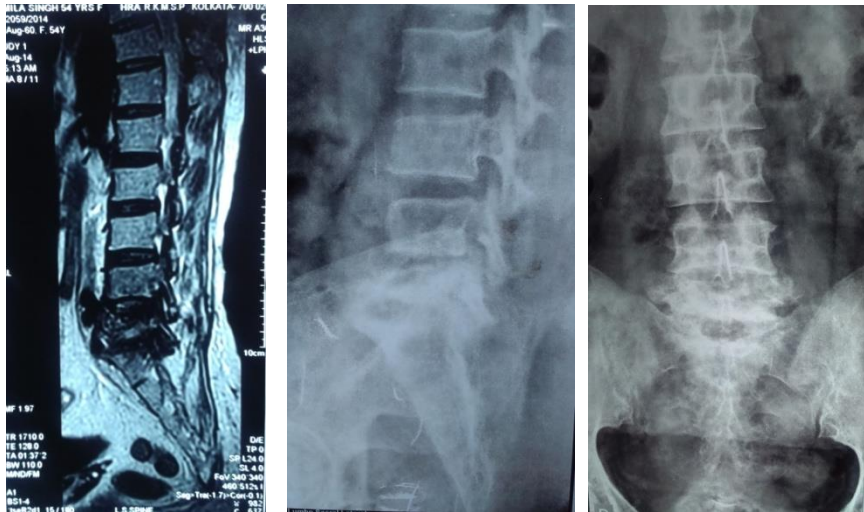
7 days post op X-rays with growing rod construct



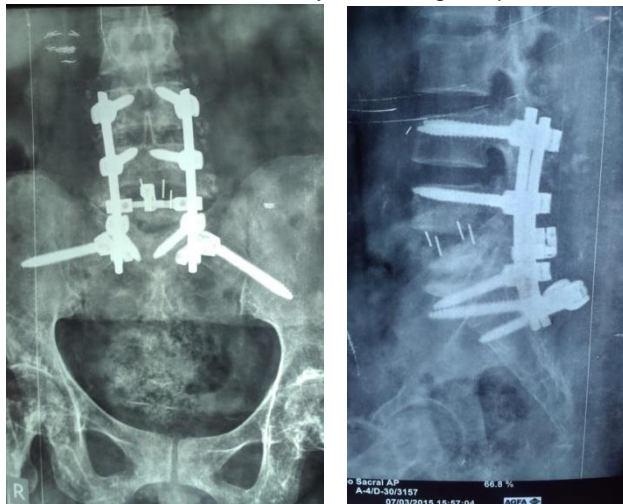
Heather with neural monitor

12. Urmilla Singh, 55year/female, L4 to S1 TB spine with weakness in the left leg and unable to ambulate due to pain in her back and legs. She underwent posterior alone surgery with debridement and Posterior Lumbar Interbody fusion with cages and posterior L3 to S1 instrumented fusion. She had two units of blood transfusion post-operatively. She was commenced on Anti TB medication in the 2nd day after surgery. She recovered gradually and was discharged home in 3weeks.

Everyone finished the day at 10PM. All retired to Tolly Club and had dinner at the club.



MRI scan & X-rays showing suspected TB lumbar spine

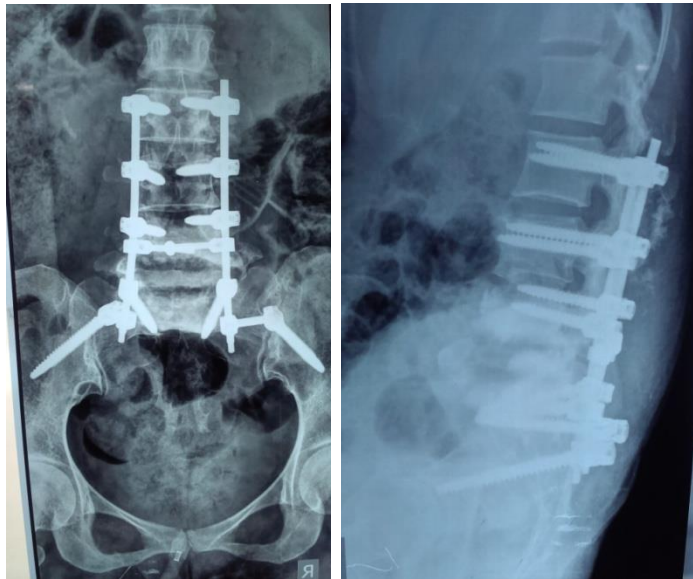
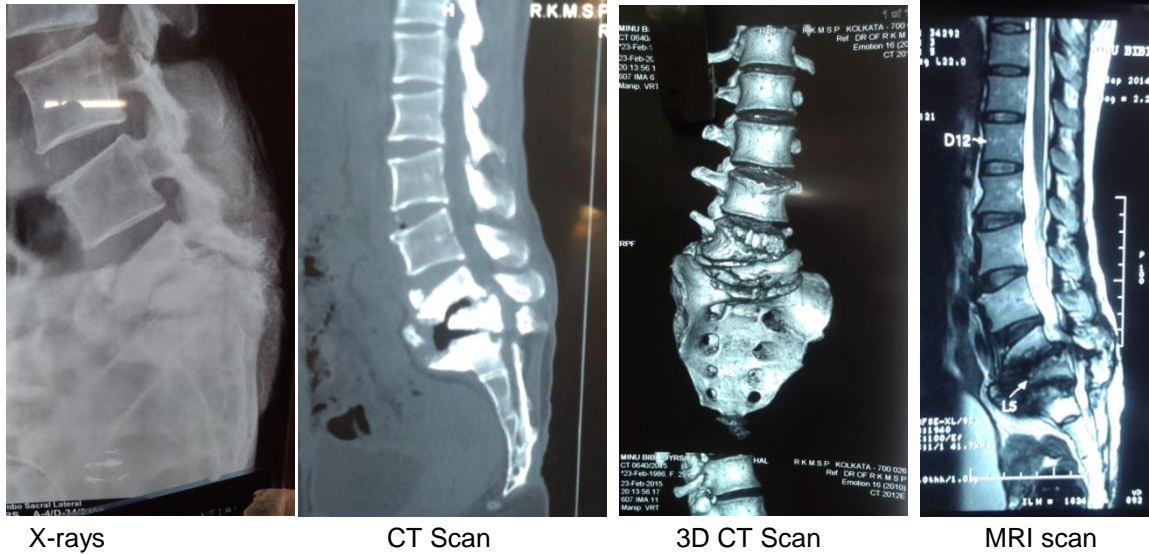


Immediate post-op Xrays

26th Feb 2015 (Thur)

Today was the final day of surgery and our last case for this year.

13. Minu Bibi, 29year/female, L4 to S1 TB spine with weakness in both legs and unable to ambulate due to pain in her back and legs. She underwent posterior alone surgery with debridement & postero-lateral fusion with instrumentation from L2 to S1. She had two units of blood transfusion post-operatively. She was commenced on Anti TB medication in the 2nd day after surgery. She recovered gradually and was discharged home in 3weeks.



Immediate post op X-rays showing the L3 to S1 fixation

An early finish by 630PM allowed all to go to Tolly club. Everyone went to the farewell dinner at the Calcutta Club which was organized by Dr N P Debroy (senior retired Orthopaedic Surgeon) since he was the member. Residents along with the team OSS enjoyed the Punjabi cuisine at the club. Everyone had a great night.

27th Feb 2015 (Fri)

Everyone return to the hospital for the last time. The team made rounds on all the patients and discuss further post-operative care with the resident orthopaedic staff and Dr. Debnath. All the patients are doing well. The team packs up supplies and instruments and return them to the store room. Everyone went to the Dr Debnath's home and his mother had cooked again a good Bengali cuisine meal for the team.

They return to the Tollygunge club to pack their personal belongings and begin the journey to the airport by 530PM.

All the team members look forward to returning next year to see the progress our patients will make. The gratifying feeling in these 2 weeks has been immense and our grateful patients make the effort to thank us with their smile.



Team members with three girls with scoliosis



Three girls with scoliosis who had undergone corrective surgery last year

Dr Ujjwal K Debnath