

ACTIVITY REPORT of OPERATION STRAIGHT SPINE Ganga Hospital, Hisar, Haryana 28th Nov to 4th Dec 2021



This Activities Report includes a description and pictures of the surgeries performed on patients

Prepared by: Prof (Dr) Ujjwal K Debnath,MS(Orth), FRCSG, FRCS (Tr & Orth), DM (Orth)

Team Members for OSS 2021:

1. Prof (Dr) Ujjwal K Debnath, Consultant Orthopaedics Spine Surgeon
2. Col (Dr) Sishir Kumar, Consultant Orthopaedics & Spine Surgeon,
3. Dr Tarun Chabra , Consultant Orthopaedics & Spine Surgeon
4. Dr Rakesh Prasad, Orthopaedic Surgeon
5. Dr Mrityunjay Deka, Orthopaedic Surgeon
6. Dr Deepshikha Sharma, Consultant Anaesthetist
7. Dr Lokesh , Consultant Anaesthetist
8. Manish Pandey (Neural monitor technician)
9. Tapas Pandey (Neural Monitor technician)
10. Arnab Chakraborty (Scrub Nurse)
11. Jahed Parvez (Implant technician)
12. Saikat Das (Team Manager)

Sponsors:

We would like to acknowledge our sponsors who generously donated to support Operation Straight Spine 2021.

Thank You!.....

- 1. Globus Medical Inc., USA**
- 2. Operation Straight Spine Trust , Kolkata, India**
- 3. Ganga Hospital, Hisar, Haryana, India**

27th Nov 2021

We arrive from Kolkata via Delhi late at night. It took us 5hours travel by road transport from New Delhi airport.

28th Nov 2021

A spinal deformity symposium was arranged with local Orthopaedic Surgeons from Hissar. Faculty of speakers came from New Delhi – Dr Neeraj Gupta from Indian Spinal Injuries centre and Dr Nishank Mehta, from AIIMS. Dr Aditya Banta from Max Hospital, Chandigarh, and Dr Ashini Ummat from Bhatinda. Col (Dr) Sishir Kumar, came from New Delhi for the surgical workshop.

A press meeting was followed by 4hour spinal deformity symposium was held on 28th Nov 2021. Dr Tarun K Chabra provides the services in Ganga Hospital for Special Surgery, Hisar, ranging from diagnosis, surgical intervention, post-operative care, physiotherapy and rehabilitation, to children and adults suffering from musculoskeletal diseases or disorders with an aim to improve the quality of life. OSS trust has supported the spinal surgical workshop and are joining hands with Dr Tarun Chabra at Ganga Hospital for Special Surgery, Hisar to develop a “*Scoliosis screening and awareness program*” in schools of Haryana.

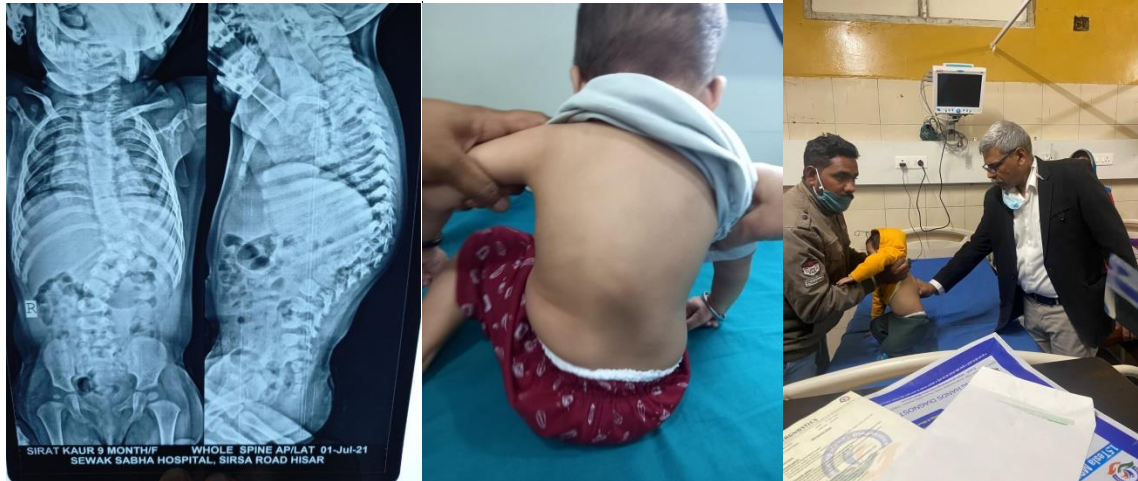

Mr Ashok Garg, IAS, Chairman of Municipal Corporation (Hisar), & Dr Parveen Chawla, Consultant Orthopaedic Surgeon , of Hisar presented mementos to the faculty.

A ward round was taken after the symposium to see all the patients admitted.

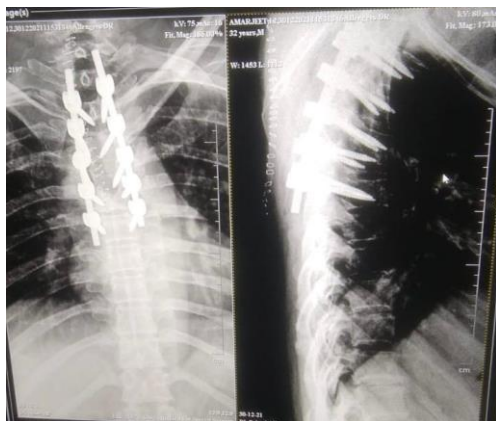
29th Nov 2021

A 1 year old child with congenital scoliosis was examined. He had D11 hemivertebrae. This child's parents were advised to wait till the child grows to 3years and get the hemivertebrae removed and correct the short segmental spinal kyphoscoliosis.



Case 1: D11 Hemivertebrae in a 1year old boy

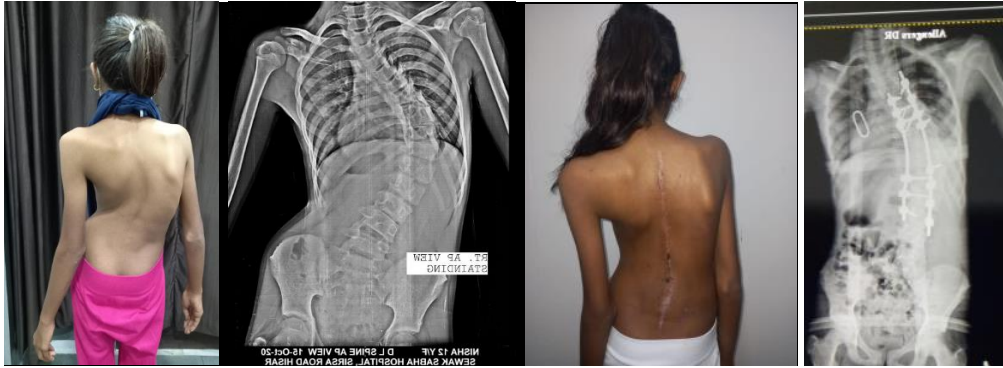Case 2: A 32year old man with TB spine (D4/5) with complete paraplegia and bladder dysfunction. MRI confirmed collapse of D5 with cord compression. He underwent surgical decompression with spinal fixation from T2 to T7.



After a long day of preparing the Operation Theatre, we finally could do the surgery after 3PM. There was no complications.

30th Nov 2021

Case 3: A 14 year old girl who was waiting for last 2 years had progressive adolescent Idiopathic Scoliosis with severe right sided scoliosis (Lenke V) with a Cobb angle of 95°. She underwent posterior Spinal instrumented correction and fusion from T4 to L3 under Spinal cord monitoring.

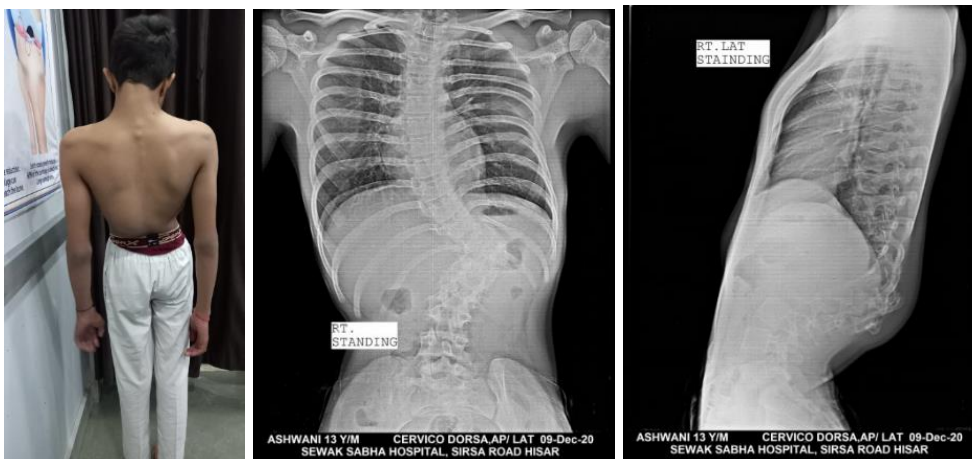

This was the first reported case of scoliosis surgery in Haryana. The family and community were pleased with the outcome. She is able to stand up and walk with a balanced spine.

1st Dec 2021

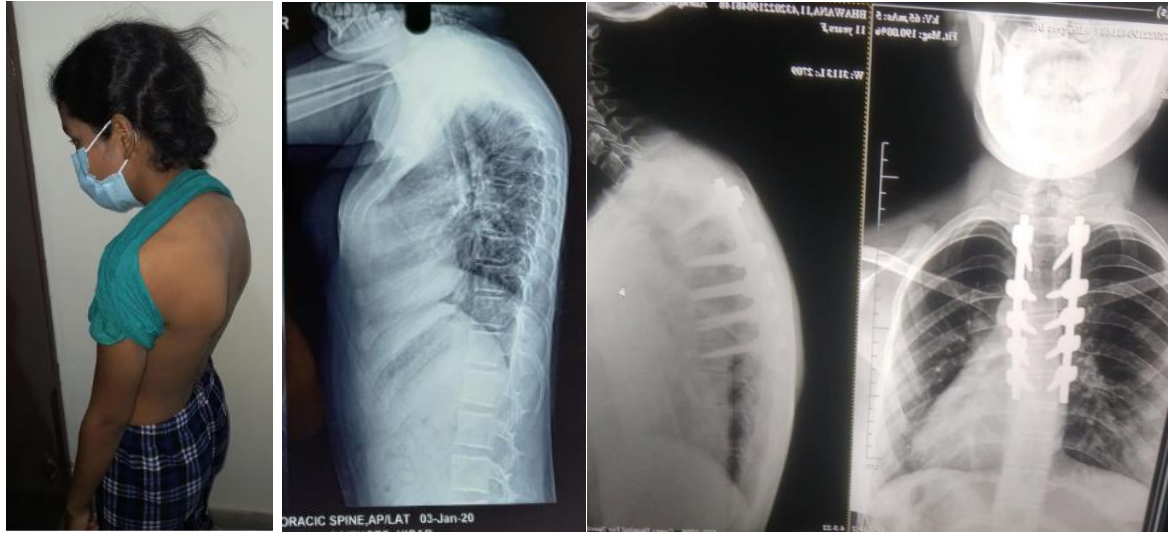
We had post op ward rounds. No complications were observed in either of the patients. We had to get confirmation from our anaesthetist who confirmed to do surgeries on the next 2 days.

Case 4: A 14 year old who had a kyphoscoliosis with a wedge Hemivertebrae at D12. He had a tethering of spinal Cord at L1 with a diastem. Neurological examination revealed weakness in left leg and was unable to balance himself. Therefore, we counseled the patient's family that he requires neurosurgeon to untether the cord. The spinal surgeons can do the surgical correction after.



2nd Dec 2021

Case 5: A 14year old girl with progressive post tuberculous kyphosis at D4. She underwent posterior corrective osteotomy and instrumented fusion from T2 to T6.



She had uneventful post op recovery.

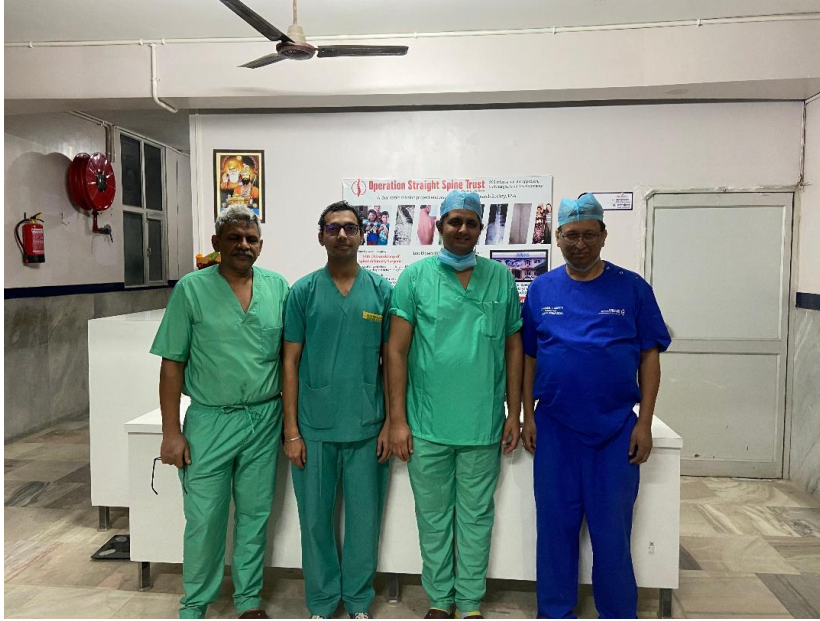3rd Dec 2021

We had no other spinal surgical cases to do. We supported Dr tarun Chabra by doing 3 complex hip, knee and hip surgery.

4th Dec 2021

We had a morning Press meeting. A successful OSS 21 campaign was well applauded by the local team and community of Hisar.

We started back for New Delhi to fly back to Kolkata same evening. We were pleased with the outcome and the great support provided by Globus Medical Team.



Dr Sishir Kumar (Spine Surgeon from Delhi), Dr Lokes (Anesthetist), Dr Tarun Chabra from Hisar and Prof (Dr) Ujjwal Debnath (OSS, Kolkata)

A big thank you for the whole team of OSS 2021 who came together to make a successful surgical workshop which is acknowledged by Dr Tarun Chabra, Director of ganga Hospital, Hisar.

