

# ACTIVITY REPORT of OPERATION STRAIGHT SPINE

Jagannath Gupta Institute of Medical  
Sciences (JIMSH), Budge Budge,  
Kolkata

17<sup>th</sup> to 23<sup>rd</sup> Apr 2022

This Activities Report includes a description and pictures of the surgeries performed on patients



Prepared by: Prof (Dr) Ujjwal K Debnath, MS(Orth), FRCSG, FRCS (Tr & Orth), DM (Orth)



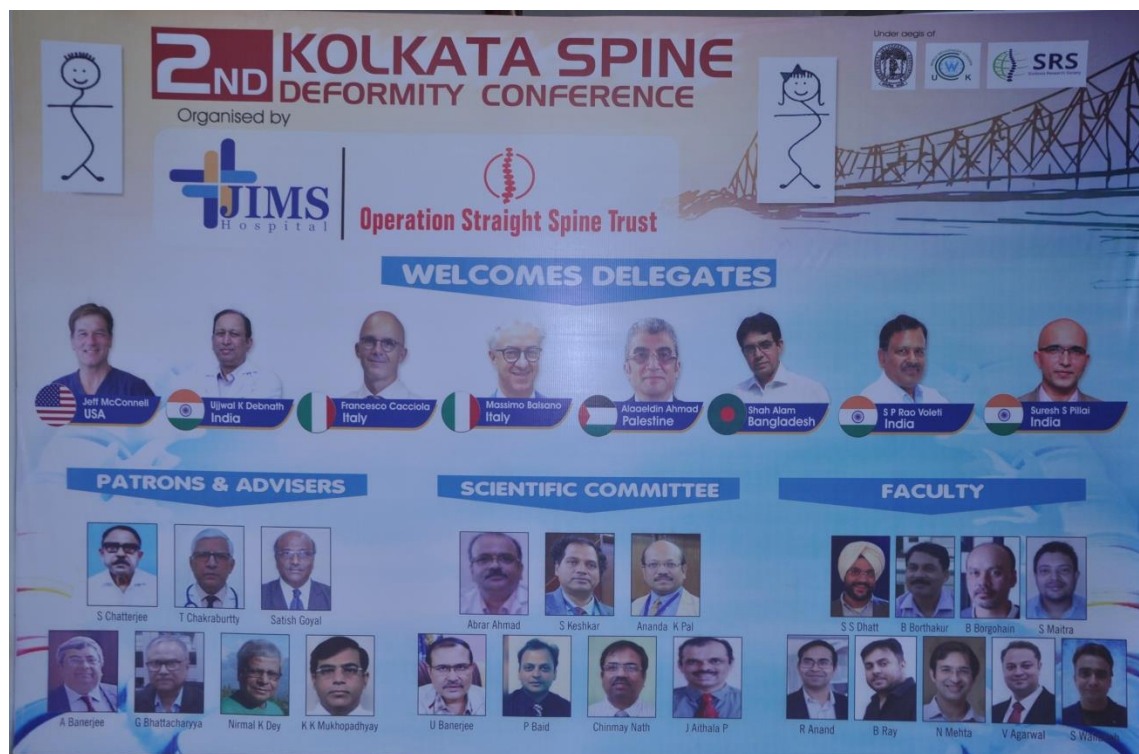<https://oss.org.in> ,  +91 9051588823

# Team Members for OSS 2022

Lead: Prof (Dr) Ujjwal K Debnath, Consultant Orthopaedics Spine Surgeon

## International Faculty

S.No.	Name	Designation	Address
1.	Dr FRANCESCO CACCIOLA	CONSULTANT NEUROSURGEON	SIENNA, ITALY
2.	Dr ALAELDIN AHMAD	CONSULTANT PAEDIATRIC SPINE SURGEON	RAMALLAH, PALESTINE
3.	Dr MASSIMO BALSANO	CONSULTANT SPINE SURGEON	VERONA, ITALY
4.	Dr MD SHAH ALAM	CONSULTANT SPINE SURGEON	DACCA, BANGLADESH



VISITING SPINAL FELLOWS: Dr Jaydeep Ghosh (Guwhati)

Dr Piyush Gadegone (Chandrapur, Maharashtra)

Dr Sagar Mukherjee (Sonarpur, WB)

Dr Tarun Chabra (Hissar, Haryana)

Dr Nitu Borgohain (Shillong, Meghalaya)

Dr Manoj Midha (New Delhi)

## National Faculty

S.No.	Name	Designation	Address
1.	Dr ANANDA K PAL	PROF & HEAD OF DEPT	IPGMER, KOLKATA
2.	Dr SANJAY KESHKAR	PROF & HEAD OF DEPT	ESCI MEDICAL COLLEGE,JOKA
3.	Dr NIRMAL K DEY	PROF & HEAD OF DEPT	JIMSH, BUDGE BUDGE
4.	Dr BIPUL BARTHAKUR	PROF & HEAD OF DEPT	NORTH-LAKHIMPUR MEDICAL COLLEGE
5.	Dr SARVDEEP SINGH DHATT	PROFESSOR	PGIMER, CHANDIGARH
6.	Dr GAUTAM BHATTACHARYYA	PROF & HEAD OF DEPT	NRS MEDICAL COLLEGE, KOLKATA
7.	Dr KIRON K MUKHOPADHYAY	PROFESSOR	NRS MEDICAL COLLEGE, KOLKATA
8.	DR SOUVIK MAITRA	ASSOCIATE PROF, ANAESTHESIA	AIIMS, NEW DELHI
9.	DR NISHANK MEHTA	ASSIST PROF, SPINE/ORTH	AIIMS, NEW DELHI
10.	DR SURESH PILLAI	CONSULTANT SPINE SURGEON	BABY MEMORIAL HOSPITAL,CALICUT
11.	DR BHASKAR BORGOHAIN	PROF & HEAD OF DEPT	NEIGRIHMS, SHILLONG
12.	DR SURYA P RAO VOLETI	CONSULTANT SPINE SURGEON	MEDICOVER HOSPITAL, HYDRABAD
13.	DR ABRAR AHMAD	CONSULTANT SPINE SURGEON	APOLLO HOSPITAL, KOLKATA
14.	DR CHINAMY NATH	CONSULTANT SPINE SURGEON	APOLLO HOSPITAL, KOLKATA
15.	Dr PRASHANT BAID	CONSULTANT SPINE SURGEON	APOLLO HOSPITAL, KOLKATA
16.	Dr SATISH GOYAL	CONSULTANT ORTHO SURGEON	VIIMS, AURANGABAD
17.	Dr RAHUL ANAND	ASSOCIATE PROF, ANAESTHESIA	AIIMS, NEW DELHI
18.	Dr SHAH WALIULLAH	ASSOCIATE PROF	KGMU, LUCKNOW
19.	Dr VARUN AGARWAL	ASSOCIATE PROF	ROHIKHAND MEDICAL COLLEGE, BAREILLY
20.	Dr JANARDAN AITHALA P	PROFESSOR	YENEPOYA MEDICAL COLLEGE, MANGALORE
21.	Dr BIVAS ROY	ASSOCIATE PROF, ANAESTHESIA	AIIMS, NEW DELHI
22.	Dr SHRIJITH K	ORTHO SPINE UNIT	AIIMS, NEW DELHI

## **2<sup>nd</sup> Kolkata Spine deformity conference and 15<sup>th</sup> OSS surgical workshop**

Endorsed by Scoliosis Research Society (SRS) and World Orthopaedic Concern (WOC)

Under the aegis of Operation Straight Spine Trust (OSS) & JIMSH, Budge Budge

Supported by West Bengal Orthopaedic Association (WBOA)

### **Sponsors:**

We would like to acknowledge our sponsors who generously donated to support Operation Straight Spine 2022.

### **Thank You!.....**

- 1. Globus Medical Inc., USA**
- 2. Emirates Airlines Foundation, Dubai, UAE**
- 3. Operation Straight Spine Trust , Kolkata, India**
- 4. JIMSH, Budge Budge, Kolkata, India**
- 5. Johnson & Jhonson, India**
- 6. Medtronics, India**
- 7. Gesco, India**
- 8. Jayon, India**
- 9. Nebula, India**
- 10. Pharmed, India**
- 11. Universal Nutriscience, India**
- 12. Intas, India**
- 13. Clariwell pharma, India**
- 14. Alkem Laboratories, India**

## 16<sup>th</sup> Apr 2022

The national and international faculty arrived from the morning till late night. The surgical faculty of Dr Alaaeldin Ahmad, Dr Shah Alam, Dr Masimo Balsano and Dr Francesco Cacciola arrived at the accommodation - Tollygunge club, Kolkata. We had registration of 6 Fellows for the conference and workshop. All the Post Graduate from JIMSH helped in receiving them from airport. I met them in the evening for a dinner at the club. Transportation logistics was managed by Mr Sanjay Gupta from JIMSH.

## 17<sup>th</sup> Apr 2022


In the morning, I personally went to Tollygunge club to welcome the faculty and escorted them to the venue. The 2<sup>nd</sup> Kolkata Spine deformity conference was held from 10AM at the auditorium in JIMSH, Budge Budge. All the faculty and fellows registered for the meeting had arrived. The compere for the conference was Ms Moutusi Dey, who was eloquent and presented the guests with honour.

The conference began with an introductory note by Brig (Dr) S Chatterjee, MSVP, JIMSH. Dr Ujjwal K Debnath gave an overview of OSS- past, present & future and a video showing Dr Jeffrey McConnell narrating the story of OSS.



This was followed by series of interesting talks by Dr Chinmoy Nath (*Measurements in Scoliosis*) & Dr K K Mukhopadhyay (*preop planning in AIS*). Dr Souvik Maitra gave a talk on “*Preventing cardiorespiratory complications during and after scoliosis surgery*”. Dr Sarvdeep Dhatt spoke on “*Surgery for AIS patients after skeletal maturity*” and Dr Shah Alam discussed “*Long term results and consequences in AIS*”. Dr Bipul Barthakur spoke on “*Rapid Recovery Pathway for AIS patients*”.

Dr Alaaeldin Ahmad was introduced by Dr Debnath and he gave an overview of APC technique which he has introduced and spoke on “*Growth friendly techniques in growing spine with Scoliosis*”. Subhojit Roy Mukherjee , Social entrepreneur, discussed “*Social Impact assessment in Scoliosis surgery*”. This was followed by an online live talk by Dr Bhaskar Borgohain, “*The Impact of Casting: Spine, Child and Family*”. Dr Satish Goel, WOC President, discussed “*WOC supporting Orthopaedics training in developing nations*”.



A ten (10) min Coffee break followed by the inauguration and lighting of the lamp by Mr Jagannath Gupta, Chairman JIMSH and Mr K K Gupta, Vice chairman, JIMSH.

Dr Nishant Mehta followed with a script on ‘*MCGR vs TGR – effectiveness in Indian scenario*’. Dr Surya P Bholeti spoke on “*Hemivertebra excision & fusion*” which was followed by Dr Suresh Pillai’s talk on “*Complex kyphoscoliosis in Neurofibromatosis*”.

Lunch was followed by the following talks.



Dr Ujjwal K Debnath spoke on “*Nutritional deficiencies in AIS*”. Dr Francesco Cacciola discussed the “*need for PSO or VCR in AIS surgery*”. Dr Masimo Balsano, showed his excellent work on “*Anterior thoracoscopic tethering in scoliosis surgery*”. This was followed by series of talks by Dr Shah Waliullah “*techniques of Pedicle screw/Hooks in Thoracic/Lumbar*”, Dr Abrar Ahmad “*techniques of Fixation Sacrum and Pelvis*” and Dr Prashant Baid on “*techniques of VCR*”. A short live online video “*VCR in TB Kyphosis*” was presented by Dr Janardan Aithala. The last talk of the day was by Dr Varun Agarwal who spoke elaborately “*O-arm 3D-navigation in spinal deformity surgery*”.

An hour long Saw bone workshop included pedicle fixation and sacral fixation techniques. All the Fellows and Post Graduate trainees were keen to learn from the faculty. The participants became familiar with the anatomical and biomechanical particularity, classification, natural history, conservative, and surgical options for the treatment of these challenging pathologies (spinal deformity). The content of each talks were of high standard although basic knowledge was imparted to the delegates.

It was followed by a dinner at Tollygunj Club.

## Live Surgery Workshop

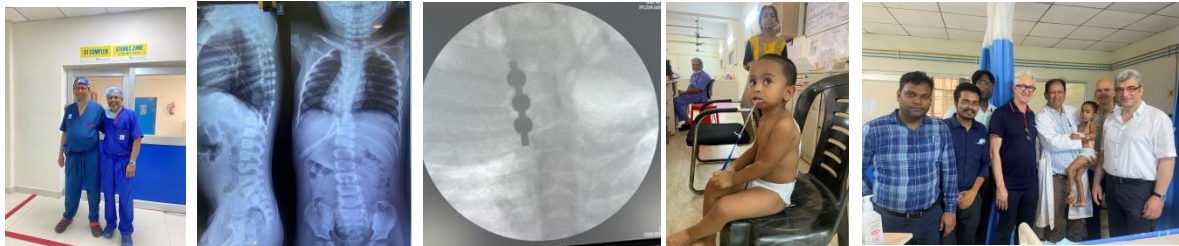
18<sup>th</sup> Apr 2022

With support from the organizing chairman Mr K K Gupta, I had organized for two simultaneous Operating Rooms to be engaged with two cases. Two live TV monitors with microphones from two Operating Rooms were arranged in the surgeon's room for Fellows and Residents to interact with the operating team. We arranged for all the patients to be seen and consulted by our foreign faculty. We planned for the week ahead.

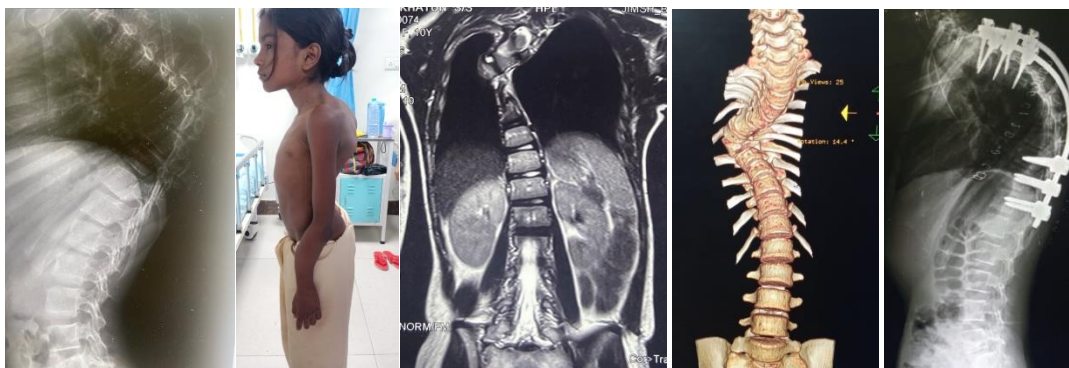
We had two patients who required Dr Alaa's advice. One was Tithi Pan (Early Onset Scoliosis) who had undergone Growth rods (Active Apex correction technique) in 2020 after removal of previous growth rods. It was observed that she was still growing and therefore the family was advised to wait till the growth is complete. The other was Trisha Den who underwent surgery in 2020 for EOS with Active apex correction. She was growing well and Alaa advised to leave her alone.

I escorted the team from Tollygunge club to JIMSH at around 9AM.

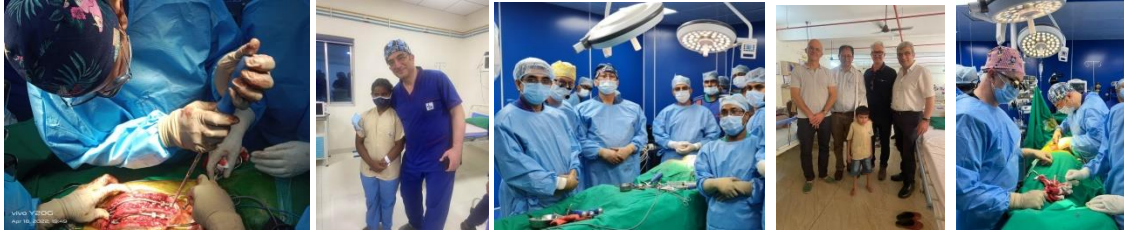**Case 1:** A 2½ year-old boy had a Hemivertebrae at D10/11 underwent anaesthesia by Dr Souvik Maitra (AIIMS) and Dr Barnava Pal (JIMSH). Dr Surya P Bholeti & I did a hemi-epiphyseodesis at the Hemivertebrae on either side followed by pedicle fixation and compression on the convex side.



**Case 2:** A 11-year-old girl with neurofibromatosis & complex dorsal kyphoscoliosis underwent an in situ fusion. She had been anaesthetized by our expert team. Continuous spinal cord monitoring was done by the team.



First stage anterior discectomy and fusion was followed by second stage posterior fixation. Dr Suresh Pillai, an expert in spinal deformities in neurofibromatosis performed the surgery with my assistance. It took us almost nine (9) hours to complete the surgery successfully.

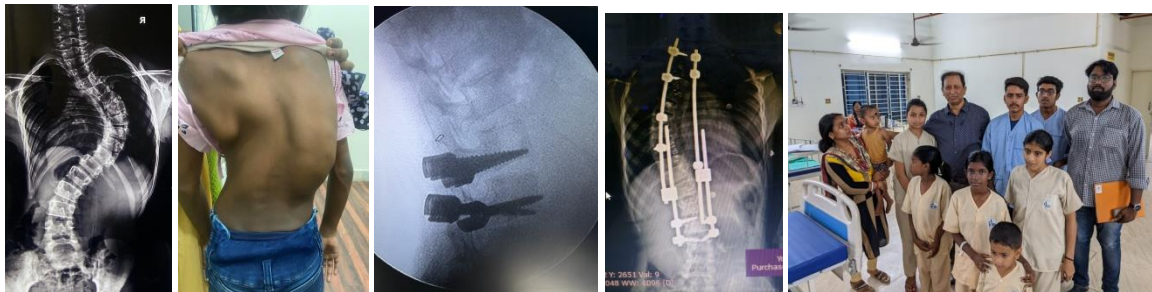

The foreign team (Dr Alaa, Dr Francesco and Dr Massimo) were invited at the West Bengal Orthopaedic Association where they were felicitated in the evening.

**19<sup>th</sup> Apr 2022**

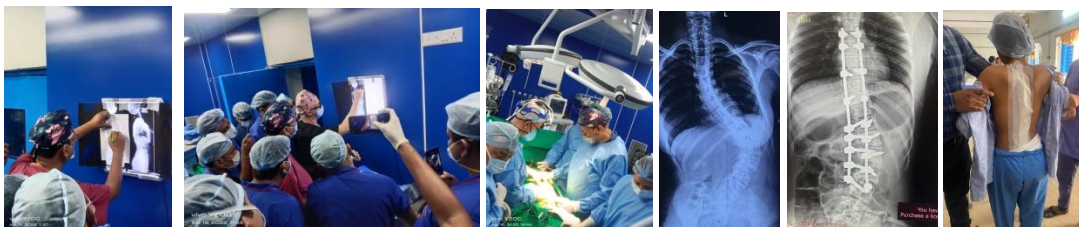Today we had two cases of AIS.

**Case 3:** A 12 year old girl with dorsal lumbar right sided curvature of 80° (AIS - Lenke 1C). It was decided to do growth rods application on her. She had been anaesthetized followed by positioning and Neural monitoring lead application. She underwent the APC technique of Dr Alaaeldin, Dr Massimo and Dr Shah Alam along with Fellows formed a team to perform the surgery. Proximal and distal pedicle screw insertion was performed through minimal incision technique.



**Case 4:** A 16year old girl with Lenke 5C AIS and a right sided thoracolumbar curvature (90°) from T3 to L4 was anaesthetised in the 2<sup>nd</sup> OR. We had preoperative discussion and teaching session with the planning of the case. All the fellows and residents were taking part actively.

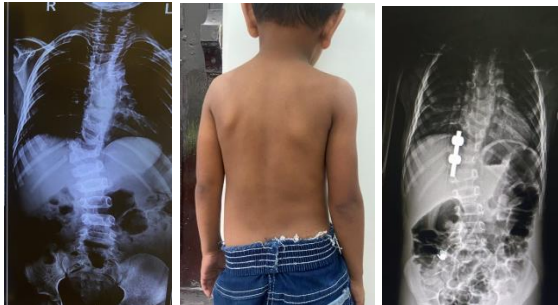Surgery was performed through a posterior approach with curve correction and instrumented spinal fusion from T4 to L4. Dr Francesco and I performed the operation. She had 90% correction of her spinal deformity on table.



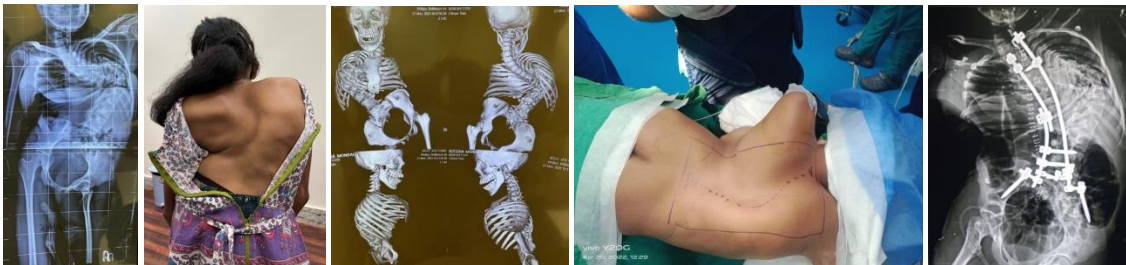

20<sup>th</sup> Apr 2022

**Case 5:** In the 1<sup>st</sup> OR, a 5 year old boy underwent epiphysiodesis and pedicle fixation for congenital scoliosis with Hemi V at D11 on right side. He had uneventful post-operative recovery.

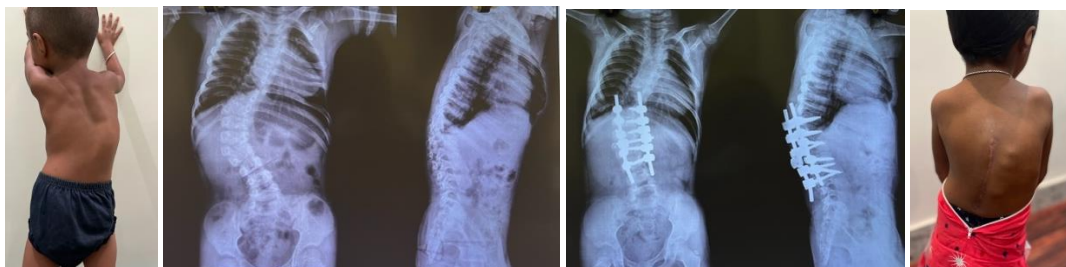


**Case 6:** Bitisha Mondal, 27year old with a neglected severe congenital scoliosis (Cobb angle - 140°) with cardio-pulmonary compromise and a right leg Amelia. She could walk with a prosthetic on her right leg. The family and patient was given the prospective risks of her getting paralysed during surgery because the spinal cord was at risk. But the patient was very brave and wished to continue with the surgery. She had in situ fixation of her deteriorating spinal deformity. There was no attempt to do the correction. During surgery she had reduced signals in the left functional lower limb by 40%. The surgery was completed but post-operatively she had no motor function of her left lower limb. She had incontinence as well. But her anal tine was normal and had a good reflex. So it was decided to leave her alone and no further surgery in the form of removal of implant was undertaken. Over the next 3weeks she became continent and was moving her ankle and toes. At the end of 6 weeks she had been able to move her left knee.

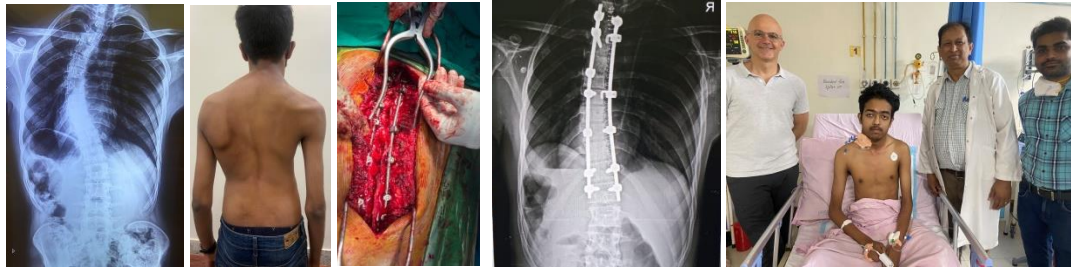


21<sup>st</sup> Apr 2022

**Case 7:** In one OR, Dr Alaaeldin and Dr Masimo performed the surgery on the 4year old girl with congenital scoliosis due to a right sided D11 and a L2 hemivertebrae. She underwent excision of hemivertebrae and spinal fixation to correct the deformity. She had an uneventful post-op recovery. Came to visit in my clinic at 4weeks and she was excited and very talkative.



**Case 8:** A 15year old boy with a upper dorsal right sided scoliosis (Cobb - 65°) and a syrinx visible on MRI scan underwent corrective surgery. Under neural monitoring, he had posterior spinal fixation performed by Dr Francesco and myself. He had good post op recovery.



**22<sup>nd</sup> Apr 2022**

Today we had extensive post-operative ward rounds. All patients were doing well. All the staff were very co-operative and were functioned as a good team.

In the evening we had dinner organized at our home for all the surgeons who visited Kolkata.

**Photos during the week**



OSS'22 Team at Tolly Club



Team in the ward



Mr K K Gupta, VC of JIMSH



Operation Theatre staff



Team with MSVP Dr S Chatterjee



Dr S Pillai & Spinal Fellows



OSS President Piyali Roy Burman  
COO, JIMSH – Diksha Mukherjee



Team after dinner at my residence

# MEDIA & ADVERTS



बिभिन्न चिकित्सक उच्चतर सेनापरीषद्को माध्यमबाट कर्माकायमा आयोजित हुने द्वितीय "कर्माकाय स्पष्ट रोगहरूको उपचार" एवं "अपारिजनल ट्रेट स्पष्ट रोगहरूको उपचार" १५ अप्रिल देखि सुरु हुनेछ।

Bengali News \_ 19<sup>th</sup> Apr 2022

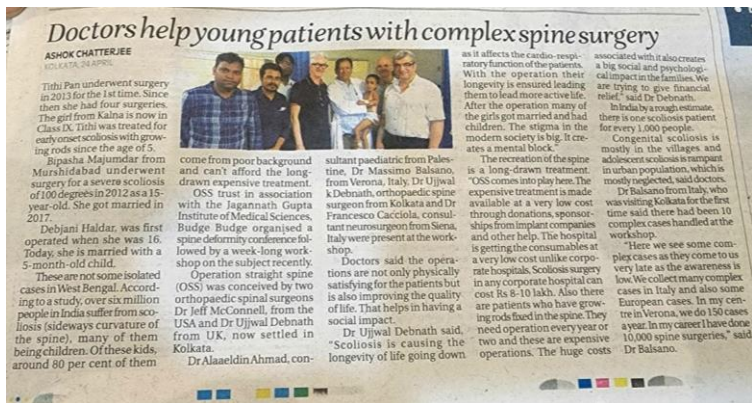

७ दिनको क्याम्प जेआईएमएसएच बजबजमा लगाइएको छ। जहाँ गरीब ३० मानिसहरूको रिडको हड्डीका पूर्ण रूपले चिकित्सा गरिन्छ।

Gujrati News \_ 19<sup>th</sup> Apr 2022



Advert at Taratola Bridge, Kolkata



Statesman news \_ 24<sup>th</sup> Apr 2022



Dr Debnath, Dr Alaaeldin, Dr Masimo & Dr Francesco at Ventura Wellness Clinic (Dr Debnath's Clinic)